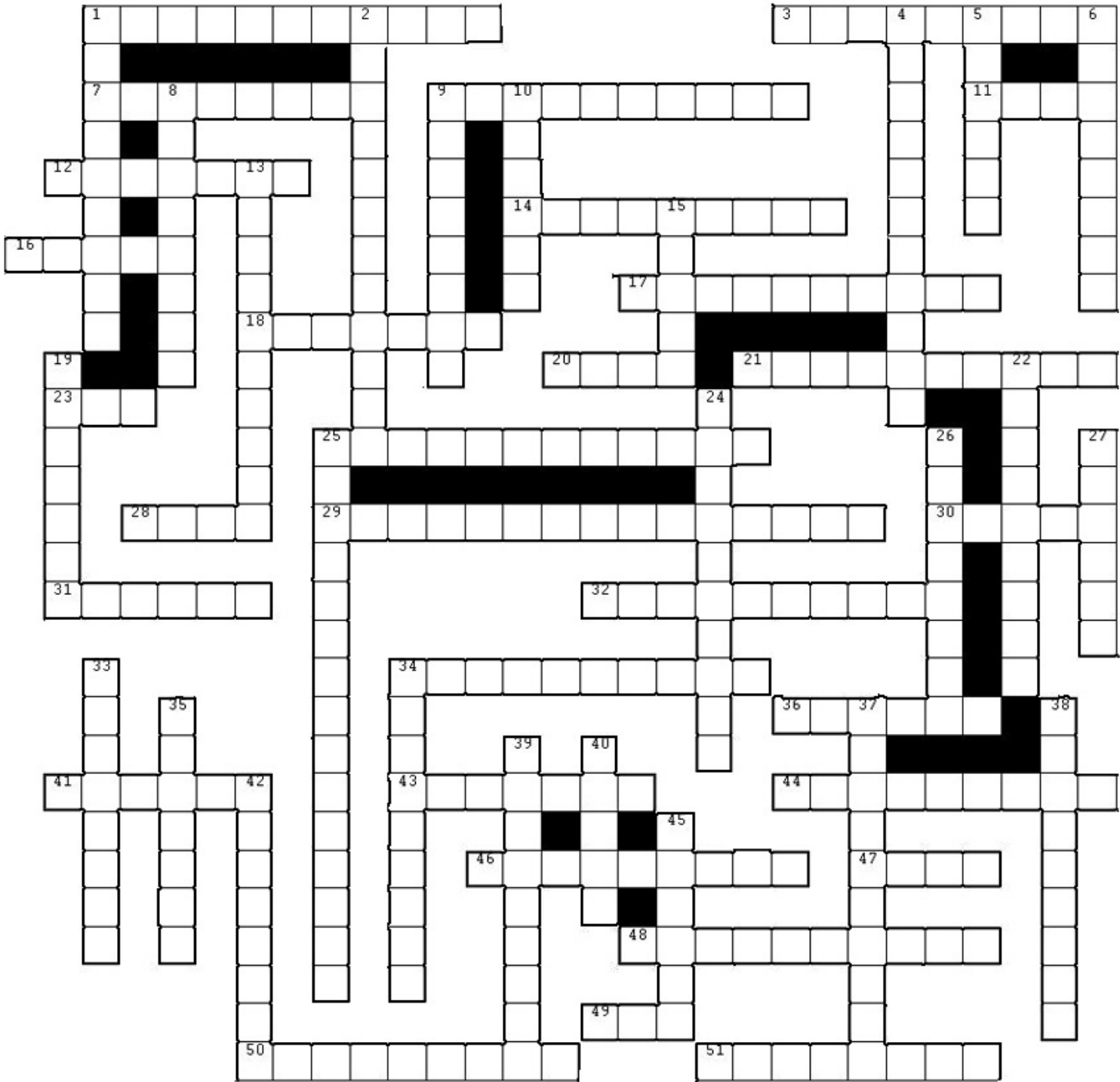


Skeletal System Puzzle



ARTICULAR
AXIAL
CALCITONIN
CALLUS
CANALICULI
CANCELLOUS
CARTILAGE
CLOSED
COMMUNUTED
COMPLETE
CONCENTRIC

DENTATE
DIAPHYSIS
ENDOCHONDRAL
ENDOSTEUM
EPIPHYSEAL PLATE
FLAT
FRACTURE
GREEN
GROWTH
HAVERSIAN
HYPERTROPHY

INTRAMEMBRANOUS
IRREGULAR
LAMELLAE
LIGAMENT
LINE
LINEAR
LONG
MEDULLARY
OBLIQUE
OPEN
OSSIFICATION

OSTEOBLAST
OSTEOCLAST
OSTEOCYTE
OSTEONS
PARATHYROID
PERIOSTEUM
PRIMARY
RED
REMODELING
SECONDARY
SEX

SHARPEYS
SHORT
SINUS
SPIRAL
STELLATE
TENDON
THYROID
TRABECULA
VITAMIN D
VOLKMANS
YELLOW